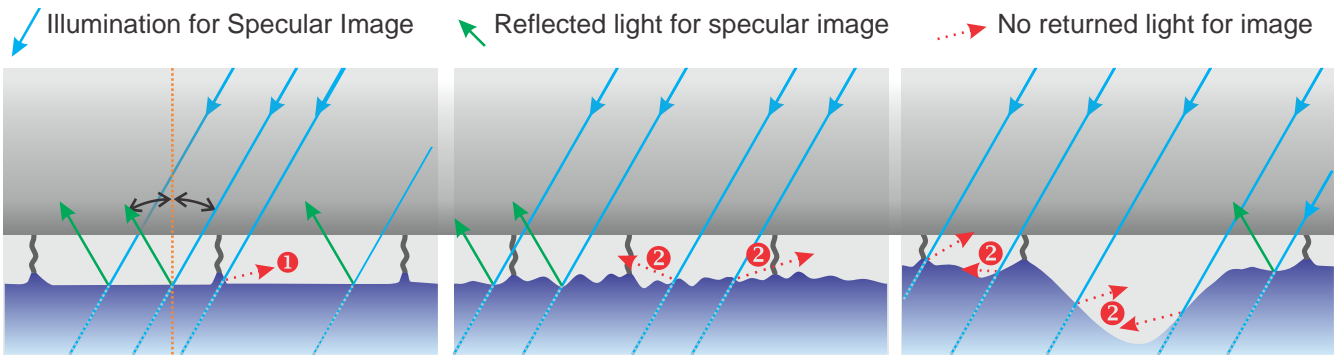


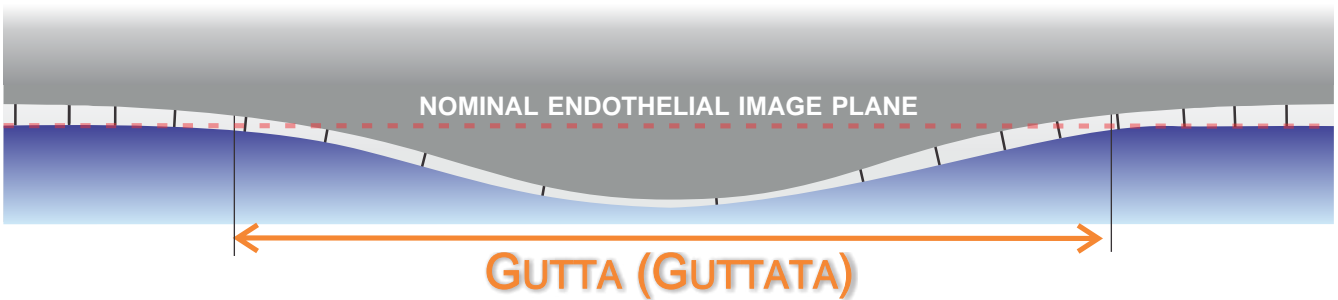
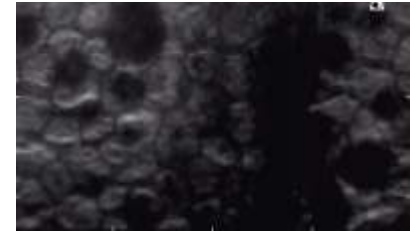

PEARLS IN THE ASSESSMENT OF COMMON SPECULAR MICROSCOPY FEATURES



① Cell borders minimally reflect light and as such are the darker features on the specular image

② Irregular surfaces scatter specular light resulting in obscured features:

- this is not a bad image, it is a clear image of a bad surface
- this is clear documentation of the endothelial interface / condition and is valuable clinical information
- when this is visible also assess adjacent areas



- are localized areas of depression of the endothelium-aqueous interface into anterior chamber
- depression is from accumulation of extra-cellular material
- appear as “dark” areas in the specular image as no light is specularly reflected back to the camera
- not an area void of cells or “holes”
- simply an area out of the plane of focus

- have an **unknown cell density** that *may or may not* be consistent with adjacent cells' density
- **area must be excluded** from the cell density (therefore morphology) calculation
- if included in density metrics will decrease ECD erroneously and all morphology data
- does not necessarily imply a low ECD
- easy (and statistically valid) methods to manage ECD count with resized frame, Center Method™, or Flex-center Method™, **only from Konan**

GUTTATA WITH NORMAL CELL DENSITY

